

Case report:

Non-tuberculous meningitis in HIV case

Dr Rajsinh Patil , Dr Akshay Dhamne , Dr Tanvi Batra , Dr Debapriya Saha , Dr Karan Jain ,
Dr Mrs V S Gokhale , Dr A L Kakrani

Department of Medicine, P.Dr D Y Patil Medical College and Hospital , Pimpri , Pune , Maharashtra , India

Corresponding author: Dr Rajsinh Patil

Abstract:

HIV can produce neurological and neuro-ophthalmic abnormalities either as a direct effect of the virus on the nervous tissue or indirectly through opportunistic infections and malignancy resulting from the immunodeficiency.¹ About 50-75% of patients infected with HIV will develop ocular manifestation with a cumulative lifetime rate of developing at least one ocular lesion of 52-100%.² Herewith we reported case of 65 years female housewife presented for complains of double vision since 10 days, more on looking left , frontal headache since 10 days, throbbing type , history of fever, low grade since 10 days , no history of weakness in upper & lower limb , no history of neck pain, head injury, seizures etc. Though non tuberculous meningitis is rare disease, can be seen immunocompromised individual and successful treatment decreases mortality in patient.

Keywords : HIV , neurotrophic virus

Background:

HIV, a neurotrophic virus enters the CNS in the early stages of infection and invades mainly microglia and macrophages, rarely the neurons. HIV can produce neurological and neuro-ophthalmic abnormalities either as a direct effect of the virus on the nervous tissue or indirectly through opportunistic infections and malignancy resulting from the immunodeficiency. About 50-75% of patients infected with HIV will develop ocular manifestation with a cumulative lifetime rate of developing at least one ocular lesion of 52-100%. Herewith we reported case of 65 years female housewife presented for complains of double vision since 10 days, more on looking left , frontal headache since 10 days, throbbing type , history of fever, low grade since 10 days , no history of weakness in upper & lower limb , no history of neck pain, head injury, seizures etc.

Case report:

65 year female housewife presented for complains of double vision since 10 days, more on looking left , frontal headache since 10 days, throbbing type , history of fever, low grade since 10 days , no history of weakness in upper & lower limb , no history of neck pain, head injury, seizures etc.

Past History:

No H/O Trauma/TB/ DM/ HTN/Asthma with Patient known case of HIV since Dec 2014

CD4 count- 502 (5/12/2014) . Patient diagnosed as Right Bell's palsy in Nov. 2014. MRI brain was suggestive of chronic ischaemic changes in bilateral periventricular white matter. Her husband died because of renal failure

General Examination:

Afebrile
PR-78/min,

BP- 120/80 mm Hg

RR-16/min

No pallor, icterus, cyanosis, lymphadenopathy, clubbing.

Systemic Examination

RS - WNL

CVS - WNL

P/A - WNL

CNS Examination:

Higher Mental Functions – Normal.

Cranial Nerves Examination –

Right eye mild ptosis present.

Right eye vertical gaze upward restricted, adduction restricted.

Left eye abduction restricted.

Both eyes pupil normal.

Both eyes corneal reflex present.

Rest of cranial nerves normal.

Fundus - Normal.

	RIGHT	LEFT
NUTRITION	Normal	Normal
TONE	UL- normal	UL - normal
	LL - normal	LL - normal
POWER	UL- 5/5	UL - 5/5
	LL - hip 5/5 knee 5/5 ankle 5/5	LL - hip 5/5 knee 5/5 ankle 5/5
DEEP TENDON REFLEX	UL- Biceps - ++ Triceps - ++ Supinator - ++	UL- Biceps - ++ Triceps - ++ Supinator - ++
	LL - Knee - ++ Ankle - ++	LL - Knee - ++ Ankle - ++
PLANTARS	flexor	flexor

SEROLOGY

HIV was +ve by ELISA, CD4 was 586/mm³.

HBsAg, anti-HCV and VDRL- negative.

CXR PA view - Normal

CSF Analysis

Clear, colourless, no clot , coagulum or cob-web seen.

Sugar-80 mg% (BSL - 109 mg %) and Protein-180 mg%,

Total cells - 10/mm³ , Predominantly lymphocytes.

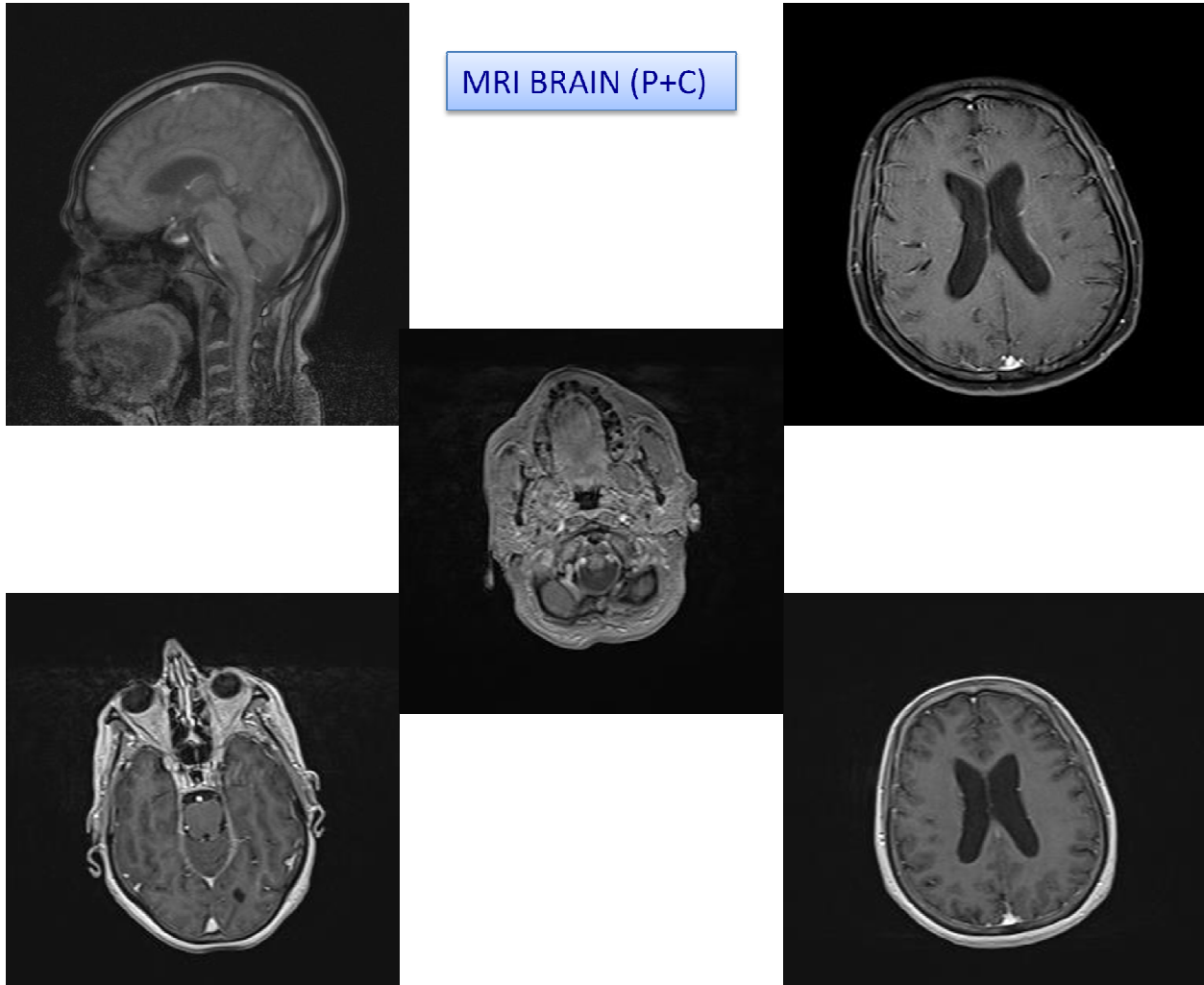
CSF for Z-N Stain- AFB not seen

CSF for Cryptococcal antigen- negative.

CSF for India ink preparation- negative

Radiological investigation-

- CT Brain Plain suggestive of Prominence of basal cisterns sulcal spaces with mild prominence of the ventricular system. Focal calcification along the tentoriumcerebelli.
- MRI Brain plain suggestive of age related cerebral atrophy.



- MRI Brain (P+C) suggestive of Chronic ischemic changes in bilateral periventricular white matter. Age related cortical atrophy. No focal enhancing lesion or abnormal enhancement seen.
- CSF for CMV antigen negative.
- ANA negative.
- Repeat CSF Analysis- Clear, colourless, no clot, coagulum or cob-web seen. Sugar-70 mg% (BSL – 110 mg %) and Protein-65

mg%, Total cells - $06/mm^3$, Predominantly lymphocytes.

- CSF for Mycobacterium tuberculosis PCR – Mycobacterium tuberculosis complex not detected.
- **CSF for Non tuberculousMycobacteria PCR- Non tuberculousMycobacteria detected**

Final Diagnosis-

- Non tuberculous Mycobacterium meningitis with cranial Nerve palsy
- Treatment – patient started on Azithromycin(500mg) + Rifampicin (450mg) and ethambutol (800mg) is given three times per week for 12 month . After 12 month of therapy patient was completely alright.

Discussion

The neuro-ophthalmological manifestation result from involvement of the afferent visual pathway, the efferent ocular motor, the pupillary system and the visual centers in the brain. Toxoplasma has a predilection for involving the brainstem and thalamus and can produce nuclear third, fourth, and sixth cranial nerve palsies. CMV, Herpes simplex and herpes zoster can cause brainstem encephalitis resulting in internuclearophthalmoplegia, vertical gaze palsy, horizontal gaze palsy, 4th,6th,7th nerve palsy and nystagmus. Dorsal midbrain syndrome characterized by impaired upgaze, lid retraction (collier's sign), convergence retraction nystagmus, light near dissociation and ataxia has also been described in AIDS. Isolated and multiple cranial neuropathies have been reported from brainstem encephalitides, neoplastic meningitides, mass lesion and vasculitis. 9% of HIV related neurological disease is heralded by cranial neuropathy. Multiple cranial neuropathies can occur at the time of HIV seroconversion, and have been reported with cryptococcal meningitis, toxoplasmosis, CNS lymphoma and multifocal CMV encephalitis.^{3,4,5} Abducens nerve is the most commonly affected cranial nerve in HIV. It has been reported in toxoplasmosis, cryptococcal meningitis, tuberculosis, histoplasmosis, herpes encephalitis, primary HIV infection, and meningeallymphomatosis. Despite the

dissemination of MAI that is present with AIDS, few cases of meningitis due to NTM have been reported.MAI is now recognized as one of the more common causes of opportunistic infection in patients with AIDS.

In 1988 Wallace and Hannah suggested that 30% to 50% of patients with AIDS will have disseminated MAI at autopsy.Other NTM, including *M kansasii* have also caused disseminated disease. Reports of isolation of NTM from CSF are infrequent.Non tuberculosis mycobacterium present as chronic meningitis lead to cranial nerve palsy. (Davis LE. Tuberculous meningitis in southwest united states.Neurology 1993;43(9):1775-8). Mechanisms of pathogenesis of NTM are not very clear and have not been adequately investigated. Very low CD4 counts and defective cytokine response have been linked to severe infections in AIDS patients. The species of nontuberculousmycobacteria reported to cause meningitis include the four groups of the Runyon classification There is considerable variation in the incidence of these species: 60% were caused by MAC, 17% were caused by mycobacteria from Runyon group II, 11.5% were caused by *Mycobacterium kansasii*, and 11.5% were caused by *Mycobacterium fortuitum*.⁶

CNS involvement was usually characterized by low-grade inflammation and the presence of perivascular lesions, poorly formed granulomas without giant cells, and numerous acid-fast bacilli. There was no evidence of other opportunistic infections.Meningitis due to *M. fortuitum* has been clearly documented and related to previous CNS surgery and trauma, and a neurocutaneous fistula that lasts for years has been described in these cases; drainage and/or removal of a foreign body has been demonstrated to be the best therapy. *M. kansasii* causes disseminated disease that

is similar to meningitis due to *M. tuberculosis*. Until culture results are available, tuberculous meningitis is initially suspected in these cases when the CSF biochemical profile is consistent with lymphocytic meningitis. The majority of NTMM cases present as lymphocytic meningitis. The CSF is normal or close to normal in patients with AIDS, and polymorphonuclear cells predominate in the CSF of patients with meningitis due to *M. fortuitum*.⁷

Treatment

Treatment for *M. avium* complex is Clarithromycin or Azithromycin + Rifabutin and ethambutol is given

three times per week. Treatment for disseminated *M. avium* complex infection in AIDS patient may be lifelong in absence of immune reconstitution. At least 12 month of MAC therapy and 6 month of effective immune reconstitution may be adequate. *M. kansasii* infection can be treated with isoniazid, rifampin, and ethambutol; therapy continues for 12 month after culture conversion.

Conclusion

Though non tuberculous meningitis is rare disease, can be seen immunocompromised individual and successful treatment decreases mortality in patient.

References:

1. Brew BJ. HIV Neurology. Oxford: Oxford University press, 2001.
2. Power C, Boisse L, Rourke S, Gill MJ. NeuroAIDS: an evolving epidemic. Can J Neurol Sci. 2009;36:285-95.
3. Hollander H, Stringari S. Human immunodeficiency virus – associated meningitis. Clinical course and correlations. Am J Med 1987;83:813-6.
4. Dube MP, Hottom PD, Larsen RA. Tuberculous meningitis in patients with or without human immunodeficiency virus infection. Am J Med 1992;93:520-24.
5. Katrak SM, Shemalkar PK, Bijwe SR, et al. The clinical, radiological and pathological profile of tuberculous meningitis in patients with and without human immunodeficiency virus infection. J Neurol Sci 2000;181:116-126.
6. Fogueira L, Delgado R, Palenque E, et al. Polymerase chain reaction for rapid diagnosis of tuberculous meningitis in AIDS patients. Neurology 1995;45:1425-7.
7. Satishchandra P, Mathew T, Gadre G, Nagarathna S, Chandramukhi A, Mahadevan A, Shankar SK. Cryptococcal meningitis: clinical, diagnostic and therapeutic overviews. Neurology India 2007;55: 226-32